Detection of Optic Disc in Fundus Images using K-mean clustering with Outlier Removal Method

Ananthi.AV
School of Computer Science & Engg
VIT, India
ananthia.v@018@vitstudent.ac.in

*J.Dheeba
School of Computer Science & Engg
VIT, India
dheeba.j@vit.ac.in
*Corresponding Author

2023 International Conference on Innovations in Engineering and Technology (ICIET) | 979-8-3503-0999-7/23/$31.00 ©2023 IEEE | DOI: 10.1109/ICIET57285.2023.10220815

Abstract — Diabetic retinopathy is a retinal disorder characterized by the pathological involvement of the blood vessels situated in the inner region of the retina. DR initially causes no symptoms or mild symptoms of vision problems, if left unnoticed, will lead to blindness. Ophthalmologists examine the fundus images showing the evolution of DR to look for any anomalies. Multiple strategies for supplementing the ophthalmologist with automated DR identification have been proposed in recent years. An important step towards early DR prediction is the optic disc (OD) segmentation, which can be challenging for any computer aided retinopathy prediction system. This study presents an improved clustering technique using k-means for finding outliers in clustered data. The algorithm is implemented on a benchmark dataset as well as a collection of real images obtained from hospitals. The efficacy of the algorithm was evaluated through experimental comparisons with alternative methods. The results presented show a considerable increase in the accuracy for segmenting the OD with less segmentation error.

Keywords— ***Diabetic Retinopathy, Machine learning, K-Mean clustering, Fundus image, Optic disc segmentation***

I. Introduction

Diabetes can lead to diabetic retinopathy, which damages the retina's blood vessels and can impair eyesight. Approximately 3 million individuals over the age of 40 have DR, and this prevalence is higher among those who have been diagnosed with diabetes [1]. When there is poor regulation of blood sugar levels, there is a fluid leakage in the blood vessels that get stored in the retina. This phenomenon results in the manifestation of retinal edema and, in certain instances, the proliferation of additional retinal blood vessels. The longer a patient has diabetes, the higher the likelihood of developing retinopathy. The progression of retinopathy is significantly influenced by the length of diabetes. This number will increase by 11,350,006 individuals in 2030. Diabetic retinopathy presents itself in two discernible forms: non-proliferative diabetic retinopathy (NPDR) as the initial manifestation, and proliferative diabetic retinopathy (PDR) as the advanced manifestation. Microaneurysms, haemorrhages, hard exudates, and cotton wool spots are clinical manifestations that are employed in the diagnostic process of non-proliferative diabetic retinopathy (NPDR). Ophthalmologists evaluate the severity of diabetic retinopathy (DR) through a comprehensive physical examination and the analysis of colour fundus images. Without the use of computer aided diagnosis systems (CAD), mass diagnostic screening is very difficult.

Over more past decades, the incidence of this vision threatening disease has been increasing worldwide at a persistent rate [2]. In order to diagnose DR, ophthalmologist look for any abnormalities by accessing the patient's eye image (fundus image), and use this information to classify the disease. Any classification system that uses medical imaging data must be properly trained in order to produce correct findings, which is a difficult undertaking given that these data are frequently obstructed. Ophthalmologists use a non-invasive diagnostic technique that uses seven standard field of view for detection of DR using stereoscopic color fundus photography. The demand for computer-aided diagnostic (CAD) systems for diabetic retinopathy has increased due to a lack of specialists in rural areas.

Recent advancements in deep learning have made it possible to analyze medical images for conditions like breast cancer, skin cancer, lung cancer, and eye disease. Currently, the most used technique for classifying diseases in medical imaging is Convolutional Neural Networks (CNN). Before performing classification in fundus images, CAD systems are subjected to pre-processing, which increases the accuracy of the classification system. Notable pre-processing in automatic detection of DR includes Optic disc segmentation, which is occluded with blood vessels. The initial stage in a decision support system involves the identification of the optic disc (OD) in the fundus image, as well as the identification of the blood vessels. In many researches, Otsu thresholding is used for removing the OD and blood vessels [3]. The separation of the optical density from the red channel is achieved by utilising bits six, seven, and eight. Following the initial segmentation process, the blood vessels within the identified region are eliminated using median filtering. This technique effectively enhances the pixel smoothing procedure [4]. Studies demonstrate that an adaptive morphological technique will accurately detect the OD and the OD boundary [5].

Several studies have demonstrated the efficacy of various techniques, such as fuzzy logic, contour models, artificial neural networks (ANN), and level set approaches, in effectively distinguishing between the optic disc and optic cup. The localization of OD holds significance due to the higher pixel brightness associated with the OD as well as the increased pixel intensity observed in hard exudates. This leads to increase in misclassification rate. Yu et al. [6] uses a directional matching filter and a level set approach to determine the OD, thereby differentiating the hard exudates. Most of the deep learning algorithms are trained using the high resolution images. The research works reported concentrate mainly on the high resolution retinal images and they don't consider low resolution images and hence deep neural networks has less knowledge about low resolution

Authorized licensed use limited to: KIIT University. Downloaded on March 07,2026 at 14:29:20 UTC from IEEE Xplore. Restrictions apply.

images. In real time, while capturing fundus images, the illumination and the focus will not be always the same. It changes depending on the light intensity and the clinician's expertise. Less work has been reported in the past years on segmentation in low resolution images. Pre-processing is most needed in such low resolution images is a tedious task. Wang et al. [7], utilized a CNN approach for grading the diabetic retinopathy images into multiple tasks.

Ophthalmologists typically take retinal images using non-mydriatic retinal cameras. Numerous authors noted that the hospital's detection images are of very poor quality, and ophthalmologists have trouble performing manual visual grading. In such cases of low resolution, the image quality is improved using illumination equalization , histogram equalization , Contourlet transform , and wavelet transform .

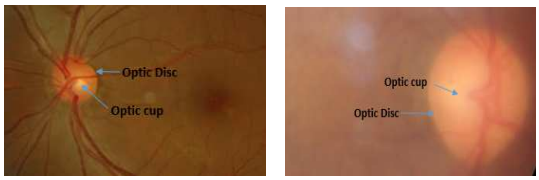

Fig. 1 Fundus image with annotated parts (a) Image with high resolution (b) Image with Low resolution

TamilNidhi and team [8] employed the Local Binary Pattern (LBP) analysis technique to detect diabetic retinopathy (DR). Subsequently, the image underwent preprocessing steps, including non-illumination correction and a bi-histogram. Using PHOG and SURF characteristics that were derived from fundus images following contrast limited adaptive histogram equalisation (CLAHE) preprocessing, discovered DR [9]. A novel method used for preprocessing the vessels and the OD is localized, features are extracted using adaptive LBP and vessels are identified [10].

Table 1. Literature Survey

Chowdhury and Banerjee [11] proposed a technique to detect retinopathy using gamma correction methods. Zhou et al [12] developed a Multi Scale Gaussian Correlation Coefficient (MACF) method for analyzing diabetic retinopathy after preprocessing with CLAHE method. The isolation of microaneurysms from fundus images requires preprocessing, like fuzzy filtering, green channel extraction and fuzzy histogram equalization. These methods are employed in conjunction with the circular Hough transform (CHT) approach [13]. Statistical parameters are employed in the context of OD [14]. Seoud et al [15] proposed segmentation using entropy based approach, multi scale ring shaped matched filter, dynamic shape feature (DSF) and classified using linear least square regression method. Table 1 shows the detailed literature survey for OD segmentation. In summary, the majority of these works relies on high resolution images on retinal images and do not take into account low resolution images. Algorithms suffer from difficulty to acquire large amount of data due to time complexity and occlusions with background images. Figure 1 illustrates a representative high-resolution fundus image alongside a corresponding low-resolution fundus image. Table.1 gives the Literature Survey regarding various Optic Disc segmentation methods.

No	Reference	Dataset	Performance	Optic disc segmentation methods
1	[16]	Drishti-GS, MESSIDOR, RIGA	Sensitivity - 94.07%, Specificity - 99.82%, Accuracy - 99.71%	B-spline-based active contour algorithm.
2	[17]	Online dataset-RIM-ONE v.3, DRIONS-DB, and private dataset	Accuracy - 99.6%	Horizontal flip, Random perturbation & Random rotation are done in pre-processing stage DeepLabV3+ ResNet + attention gates segmentation method used for OD removal
3	[18]	BEH dataset from Bangladesh Eye Hospital, ACRIMA dataset	Accuracy – 96%	Using 'BIRME' cropping tool optical disc covered area was selected U-net model is used for segmentation
4	[19]	ORIGA, RIGA	Accuracy - 96%	The ROI ADAM approach is used for OD segmentation, which optimises the network
5	[20]	Kasturba Medical College (KMC), Manipal, DRISHTI	Accuracy - 99.6%	Gaussian filter is used for enhancing the optic disc Decision tree based segmentation is used for OD removal
6	[21]	DRIVE, STARE, DRIONS-DB, and RIM-ONE	F score - 0.94	To remove the optic cup, a glow worm swarm optimization algorithm was applied

Authorized licensed use limited to: KIIT University. Downloaded on March 07,2026 at 14:29:20 UTC from IEEE Xplore. Restrictions apply.

7	[22]	Kaggle	Accuracy – 74%	The optic disc is removed using the UOLO object segmentation approach
8	[23]	DIARETDB1	Accuracy - 93%	CLAHE is used for preprocessing. OD removal is done by open-close watershed transformation
9	[24]	DIARETDB1	Accuracy - 98%	Morphological closing and opening operation is used for OD segmentation
10	[25]	DIARETDB1, DIARETDB0	Accuracy – 98.6%	OD is identified by Circular Hough Transform (CHT)

II. PROPOSED METHODOLOGY

Analysis of retinal images includes pre-processing the image for higher efficiency. Segmentation of OD is done by partitioning the optical disc from the preprocessed image involving the application of pre-processing techniques, which are designed to correct any discrepancies in illumination during image capturing. Next phase is the OD segmentation. OD region is selected using the clustering approach and removed. The presence of the Optic Disc in the chosen sample is a result of the removal of the OD. The comprehensive procedure is depicted in Figure 2.

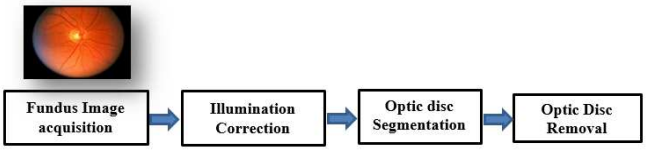

Fig. 2 Overall block diagram of OD removal

II.1. Pre-processing

The main objective of pre-processing is to facilitate the decision support system. Some more issues are caused by an image that is blurry or lacks clarity during the pre-processing stage. Basic preprocessing like constrast enhancement, green channel conversion is done on the image. The fundus photos have a resolution of 2240 x 1488 at 24 bits in JPEG format. The utilisation of the HSV colour space, which includes the three elements of Hue, Saturation, and Value, is employed for the purpose of translation. Image smoothing refers to the application of filters on an image with the purpose of eliminating noise. The utilisation of the median filter, a form of smoothing filter, is implemented for the purpose of noise reduction in the image. Histogram equalisation is widely regarded as the most efficacious real-time method for boosting the quality of a low-resolution image. The histogram offers valuable insights into the image's contrast and brightness characteristics, effectively summarizing how the intensity values are distributed. To enhance local contrast in an image, Contrast Limited Adaptive Histogram Equalization (CLAHE) is employed as a technique.

II.2. OD segmentation

Following the completion of the initial preprocessing phase, the image undergoes OD segmentation. This stage involves extracting the region of interest and subsequently applying K-means clustering to segment the optic disc (OD). In this study, we employ an improved K-means clustering technique that eliminates outliers from the ROI. Since the OD contains veins in it, the portion is subjected to outliers. The real challenge that lies in the clustering process is the outliers. Outliers are pixels that are different from the remaining similar pixel group. Instead of segregating a pixel as outliers, the degree of being an outlier will give knowledge about the pixel intensity. Segmenting the OD from the fundus image is achieved by employing K-means clustering as part of the process [26]. A dataset is divided into K distinct and exclusive groups or clusters using the K-means algorithm. A separate cluster is given to each data point. The data points and the centroid of each cluster are separated from each other by a distance that is minimized by the method. The data points are thought to be more similar to one another and closer to their centroid if the distance between them and the centroid of their cluster is lower. This reduces the overall variability within each cluster. Following the clustering process, the local outlier factor is considered in order to identify and locate any outliers within the dataset. The local outlier factor (LOF) quantifies the level of uniqueness exhibited by an entity with respect to its neighbouring pixels [27]. These are the steps:

1. Determine the Kth closest neighbor values after calculating the distance between the spots.
2. To determine the reachability distance (RD) between two points (p, q), we need to calculate the distance between these points.

$$RD(p,q) = Max\{k - distance(q), dist(p,q)\}$$

3. The subsequent equation is employed for the computation of local reachability density (LRD). The density at point P is estimated as P. The topic under consideration relates to the inverse of the mean reachability distance between a specific point, referred to as p, and the points situated within its k-neighborhood.

$$LRD_k(p) = \frac{1}{\sum_{X_j \in N_{k(p)}} \frac{RD(p, X_j)}{||N_k(p)||}}$$

4. Local outlier factor is calculated using the below equation. The highest LOF is found to be the outlier

Authorized licensed use limited to: KIIT University. Downloaded on March 07,2026 at 14:29:20 UTC from IEEE Xplore. Restrictions apply.

$$LOF_k(p) = \frac{\sum_{Xj \in N_{k(p)}} LRD_k(X_j)}{\|N_k(p)\|} \times \frac{1}{LRD_k(p)}$$

The Local Outlier Factor (LOF) score demonstrates a positive numerical value. In general, a greater Local Outlier Factor (LOF) value tends to suggest that a particular data point is regarded as an outlier[28,29].

III. EXPERIMENTAL OUTCOMES

The suggested approach's outcomes are implemented in four stages: preprocessing, OD segmentation, OD selection, and OD removal. The images with noise are moved in the preprocessing stage of retinal image. OD segmentation is an essential step in the segmented stage for identifying retinopathy symptoms. From the segmentation OD is selected and removed. It will be used for further classification.

Preprocessing stage:

In the preprocessing, image enhancement is done using various processing techniques. First Using Color Space Conversion method the raw image is enhanced. HSV, RGB and gray scale conversion methods are implemented for enhancement. The median filter is utilised to achieve smoothing effects, the computation of the system is dependent on the mean and threshold value. The application of the Contrast Limited Adaptive Histogram Equalisation (CLAHE) histogram technique is utilised to enhance the visual quality of the Optic Disc region. Following fig. 3 shows the Contrast enhancement of high resolution image i.e, image is taken from Messidor dataset .Fig. 4 is showing the Contrast enhancement of low resolution image means from real time dataset.

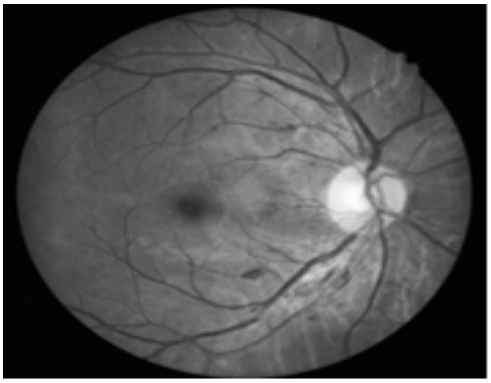

Fig. 3: Image enhancement of high resolution image Fig. 4: Image enhancement of low resolution image

OD Segmentation:

Segmentation is the dominant process of Optic Disc detection. It is working with K-mean clustering with outlier removal in the fundus images of high resolution image (Fig. 5) and low resolution image(Fig .6)

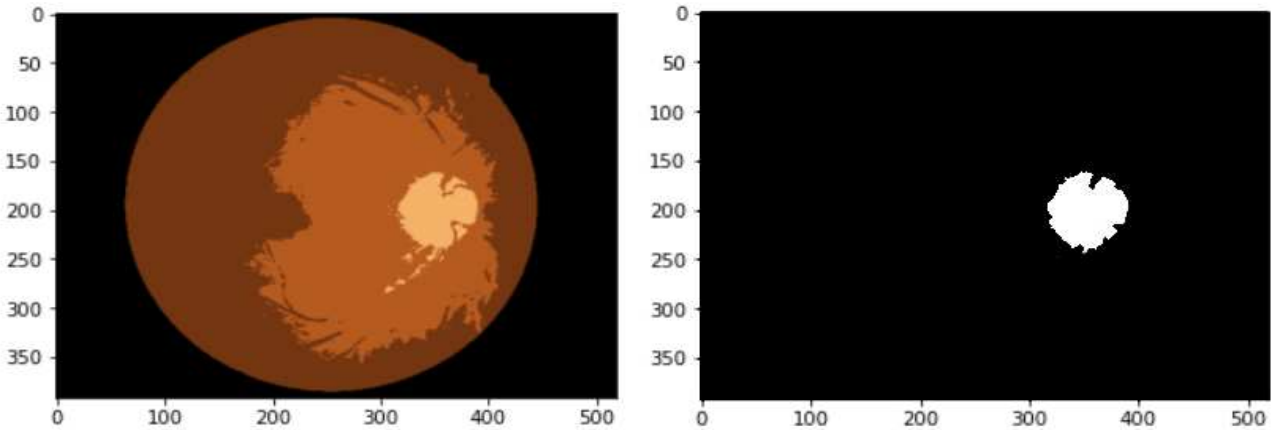

Fig:5:K-mean clustering with outlier removal of high resolution image

Authorized licensed use limited to: KIIT University. Downloaded on March 07,2026 at 14:29:20 UTC from IEEE Xplore. Restrictions apply.

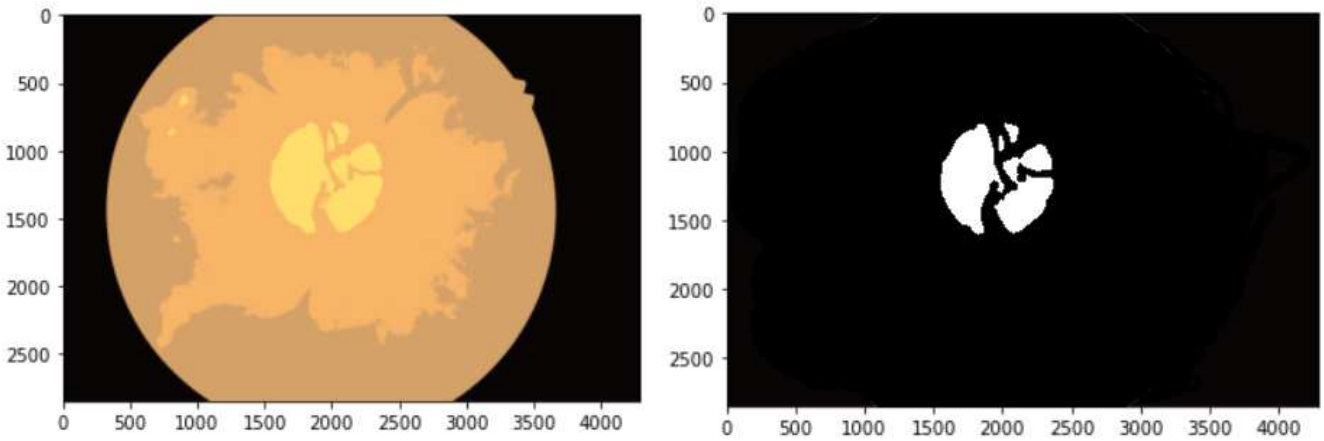

Fig:6:K-mean clustering with outlier removal of low resolution image

CONCLUSION

The utilisation of the lighting equalisation technique serves as an initial measure to enhance the overall quality of the image. With the aid of low contrast images, this technique is meant to make it easier for ophthalmologists to identify symptoms during the diabetic retinopathy screening process. The retinal fundus images undergo pre-processing techniques, specifically median filtering with histogram equalization. Ophthalmologists will be able to accurately identify diabetic retinopathy and so treat patients by segmenting and removing the optic disc.

REFERENCES

[1] Raman, R., Vasconcelos, J. C., Rajalakshmi, R., Prevost, A. T., Ramasamy, K., Mohan, V., ... & Kulkarni, S. (2022). Prevalence of diabetic retinopathy in India stratified by known and undiagnosed diabetes, urban–rural locations, and socioeconomic indices: results from the SMART India population-based cross-sectional screening study. *The Lancet Global Health*, *10*(12), e1764-e1773.

[2] Fong, D. S., Aiello, L. P., Ferris III, F. L., & Klein, R. (2004). Reviews/Commentaries/ADA Statements-Technical Review-Diabetic retinopathy. *Diabetes care*, *27*(10), 2540-2553.

[3] Wang, X., Xu, M., Zhang, J., Jiang, L., Li, L., He, M., & Wang, Z. (2021). Joint learning of multi-level tasks for diabetic retinopathy grading on low-resolution fundus images. *IEEE Journal of Biomedical and Health Informatics*, *26*(5), 2216-2227.

[4] Pathan, S., Kumar, P., Pai, R., & Bhandary, S. V. (2020). Automated detection of optic disc contours in fundus images using decision tree classifier. *Biocybernetics and Biomedical Engineering*, *40*(1), 52-64.

[5] Singh, A., Dutta, M. K., ParthaSarathi, M., Uher, V., & Burget, R. (2016). Image processing based automatic diagnosis of glaucoma using wavelet features of segmented optic disc from fundus image. *Computer methods and programs in biomedicine*, *124*, 108-120.

[6] Yin, P., Xu, Y., Zhu, J., Liu, J., Huang, H., & Wu, Q. (2021). Deep level set learning for optic disc and cup segmentation. *Neurocomputing*, *464*, 330-341.

[7] Yu, H., Barriga, E. S., Agurto, C., Echegaray, S., Pattichis, M. S., Bauman, W., & Soliz, P. (2012). Fast localization and segmentation of optic disk in retinal images using directional matched filtering and level sets. *IEEE Transactions on information technology in biomedicine*, *16*(4), 644-657.

[8] TamilNidhi, M., & Gunaseelan, K. (2018). Examining the variation of vascular structure in digital fundus images using textural pattern. *Personal and Ubiquitous Computing*, *22*, 961-970.

[9] Koh, J. E., Ng, E. Y., Bhandary, S. V., Laude, A., & Acharya, U. R. (2018). Automated detection of retinal health using PHOG and SURF features extracted from fundus images. *Applied Intelligence*, *48*, 1379-1393.

[10] Zou, B. J., Chen, Y., Zhu, C. Z., Chen, Z. L., & Zhang, Z. Q. (2017). Supervised vessels classification based on feature selection. *Journal of Computer Science and Technology*, *32*, 1222-1230.

[11] Roy Chowdhury, A., & Banerjee, S. (2017). Towards an automated approach to the detection of retinal abnormalities. *CSI transactions on ICT*, *5*, 71-78.

[12] Zhou, W., Wu, C., Chen, D., Yi, Y., & Du, W. (2017). Automatic microaneurysm detection using the sparse principal component analysis-based unsupervised classification method. *IEEE access*, *5*, 2563-2572.

[13] Rahim, S. S., Jayne, C., Palade, V., & Shuttleworth, J. (2016). Automatic detection of microaneurysms in colour fundus images for diabetic retinopathy screening. *Neural computing and applications*, *27*, 1149-1164.

[14] Morales, S., Engan, K., Naranjo, V., & Colomer, A. (2015). Retinal disease screening through local binary patterns. *IEEE journal of biomedical and health informatics*, *21*(1), 184-192.

[15] Seoud, L., Hurtut, T., Chelbi, J., Cheriet, F., & Langlois, J. P. (2015). Red lesion detection using dynamic shape features for diabetic retinopathy screening. *IEEE transactions on medical imaging*, *35*(4), 1116-1126.

[16] Gagan, J. H., Shirsat, H. S., Kamath, Y. S., Kuzhuppilly, N. I., & Kumar, J. H. (2022). Automated Optic Disc Segmentation Using Basis Splines-Based Active Contour. *IEEE Access*, *10*, 88152-88163.

[17] Bhatkalkar, B. J., Reddy, D. R., Prabhu, S., & Bhandary, S. V. (2020). Improving the performance of convolutional neural network

[18] for the segmentation of optic disc in fundus images using attention gates and conditional random fields. *IEEE Access*, *8*, 29299-29310.

[19] Islam, M. T., Mashfu, S. T., Faisal, A., Siam, S. C., Naheen, I. T., & Khan, R. (2021). Deep learning-based glaucoma detection with cropped optic cup and disc and blood vessel segmentation. *IEEE Access*, *10*, 2828-2841.

[20] Guo, F., Li, W., Kuang, Z., & Tang, J. (2021). MES-Net: a new network for retinal image segmentation. *Multimedia Tools and Applications*, *80*, 14767-14788.

[21] Pathan, S., Kumar, P., Pai, R. M., & Bhandary, S. V. (2021). Automated segmentation and classifcation of retinal features for glaucoma diagnosis. *Biomedical Signal Processing and Control*, *63*, 102244.

[22] Pruthi, J., Khanna, K., & Arora, S. (2020). Optic Cup segmentation from retinal fundus images using Glowworm Swarm Optimization for glaucoma detection. *Biomedical Signal Processing and Control*, *60*, 102004.

[23] Araújo, T., Aresta, G., Mendonça, L., Penas, S., Maia, C., Carneiro, A., ... & Campilho, A. (2020). Data augmentation for improving proliferative diabetic retinopathy detection in eye fundus images. *IEEE Access*, *8*, 182462-182474.

[24] Jadhav, A. S., Patil, P. B., & Biradar, S. (2021). Optimal feature selection-based diabetic retinopathy detection using improved rider optimization algorithm enabled with deep learning. *Evolutionary intelligence*, *14*, 1431-1448.

[25] Alaguselvi, R., & Murugan, K. (2021). Performance analysis of automated lesion detection of diabetic retinopathy using

Authorized licensed use limited to: KIIT University. Downloaded on March 07,2026 at 14:29:20 UTC from IEEE Xplore. Restrictions apply.

morphological operation. *Signal, Image and Video Processing*, *15*, 797-805.

[26] Gharaibeh, N., Al-hazaimeh, O. M., Abu-Ein, A., & Nahar, K. M. (2021). A hybrid svm naïve-bayes classifier for bright lesions recognition in eye fundus images. *International Journal on Electrical Engineering and Informatics*, *13*(3), 530-545.

[27] Gan, G., & Ng, M. K. P. (2017). K-means clustering with outlier removal. *Pattern Recognition Letters*, *90*, 8-14.

[28] Breunig, M. M., Kriegel, H. P., Ng, R. T., & Sander, J. (2000, May). LOF: identifying density-based local outliers. In *Proceedings of the 2000 ACM SIGMOD international conference on Management of data* (pp. 93-104).

[29] Luo, Y., Liu, Y., Yang, W., Zhou, J., & Lv, T. (2023). Distributed filtering algorithm based on local outlier factor under data integrity attacks. *Journal of the Franklin Institute*.

Authorized licensed use limited to: KIIT University. Downloaded on March 07,2026 at 14:29:20 UTC from IEEE Xplore. Restrictions apply.